

Review on Methods for Optic Disc Segmentation

Reshma Radhakrishnan

PG Student, Biomedical Engineering, Government Engineering College, Gandhinagar, Gujarat, India

ABSTRACT: Glaucoma is one of the leading causes of blindness in the world. Proper screening and treatment can help reduce the risk of increasing cases of Glaucoma. Common features for the detection of glaucoma are the optic disc, optic cup and neuroretinal rim. There are various methods based on morphological operations to detect these features. This paper provides a review of different methods for detecting Optic Disc

KEYWORDS: Glaucoma, Intraocular pressure, Optic Disc

I. INTRODUCTION

Glaucoma is one of the major reasons leading to blindness. This damages the optic nerve of the eye. Increased pressure of eye, also known as intraocular pressure, leads to this damage. This pressure increases when the fluid is not circulating properly within the eye. The fluid, aqueous humor, flows out of the eye through mesh-like channel. When this channel gets blocked, the fluid builds up, leading to glaucoma.

A. Types of Glaucoma:

There are several types of glaucoma. The two main types are open-angle and angle-closure. These are marked by an increase of intraocular pressure (IOP), or pressure inside the eye.

Open Angle Glaucoma:

Open Angle Glaucoma is the most common form of glaucoma.

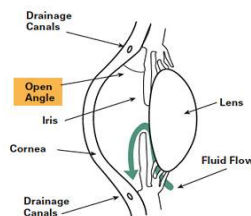


Fig. 1. Open Angle Glaucoma[6]

It is caused by the slow clogging of the drainage canals, resulting in increased eye pressure with a wide and open angle between the iris and cornea. It develops slowly and is a lifelong condition and has symptoms and damage that are not noticed. “Open-angle” means that the angle where the iris meets the cornea is as wide and open as it should be. Open-angle glaucoma is also called primary or chronic glaucoma[6].

Angle Closure Glaucoma:

It is a less common form of glaucoma.

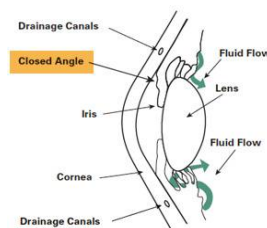


Fig. 2. Angle Closure Glaucoma[6]



International Journal of Advanced Research in Electrical, Electronics and Instrumentation Engineering

(An ISO 3297: 2007 Certified Organization)

Vol. 5, Issue 2, February 2016

It is caused by blocked drainage canals, resulting in a sudden rise in intraocular pressure with closed or narrow angle between the iris and cornea. It develops very quickly, has symptoms and damage that are usually very noticeable and demands immediate medical attention.

It is also called acute glaucoma or narrow-angle glaucoma. Unlike open-angle glaucoma, angle-closure glaucoma is a result of the angle between the iris and cornea closing[6].

Normal Tension Glaucoma:

Normal-tension glaucoma (NTG), also known as low tension or normal pressure glaucoma, is a form of glaucoma in which damage occurs to the optic nerve without eye pressure exceeding the normal range. In general, a "normal" pressure range is between 12-22 mm Hg. The causes of NTG are still unknown. For some reason, the optic nerve is susceptible to damage from even the normal amount of eye pressure[6].

Congenital Glaucoma:

This type of glaucoma occurs in babies when there is incorrect or incomplete development of the eye's drainage canals during the prenatal period. This is a rare condition that may be inherited[6].

II. METHODS

In 2013, Fauzia Khan et. al. performed a work "*Detection of Glaucoma using Retinal Fundus Images*". In this paper original image is first converted to HSV color model. From which the V plane is extracted, converted to grayscale and binary and morphological operations are applied on it to fill the gaps due to blood vessels. Gaussian filter is applied to smoothen the edges[1].

In March 2014, OakarPhyo and AungSoeKhaing proposed a work on "*Automatic Detection of Optic Disc and Blood Vessels from Retinal Images Using Image Processing Techniques*". In this paper the author converted the original RGB image into HSI image which was median filtered to remove the noise without blurring the edges. This filtered image is enhanced to overcome the uneven illumination in the image. This enhancement was followed by morphological operations and otsuthresholding to detect the optic disc[2].

In year 2010, Zhuo Zhang et. at. proposed a paper "*Optic disc Region of Interest Localization in fundus images for Glaucoma Detection in ARGALI*". ARGALI refers to Automatic Cup to Disc Ratio measurement system for Glaucoma detection and AnaLysIs. For optic disc localization, first the histogram of the grayscale image of fundus image in which the highest intensity is typically the region of interest. 0.5% of all pixels are selected as higher pixels intensities. Then the image is divided into 64 sections and the region with largest number of highest pixel intensity is marked as optic disc. A circle of radius twice the optic disc is drawn to determine the boundary of optic disc. While finding region of interest, the optic disc may be misinterpreted with the bright fringe. So it is necessary to remove it and is done by enhancing the image[3].

In February 2015, Apeksha R. Padaria and BhailalLimnasiya proposed their work on "*A Review Paper on Detection of Optic Disc Damage using Retinal Images*". In some previous methods, the retinal fundus was divided into grids and the region of interest, that is, the optic nerve head is located by finding the most appropriate grid. The new method proposed involves locating region of interest containing optic disc. Red channel is extracted from the color fundus image as it has greater visibility. Variational level set is applied on this red channel to determine the optic disc. The contours detected are occluded by blood vessels resulting in uneven contours. This unevenness is corrected by applying ellipse fitting[4].

In 2015, KokelHetalNirmal proposed a work on "*Detection and Classification of Diabetic Retinopathy from Retinal Fundus Images*", in which the optic disc was detected by extracting Red channel of the RGB image, histogram equalized, thresholded and applied morphological operations to obtain the optic mask to get the optic disc[5].

International Journal of Advanced Research in Electrical, Electronics and Instrumentation Engineering

(An ISO 3297: 2007 Certified Organization)

Vol. 5, Issue 2, February 2016

In another proposed method the image acquired from the fundus camera, which is an RGB image, is resized to 256 X 256 and preprocessed. The preprocessed image is filtered using unsharp filter. It generates sharp image by subtracting from the blurred image. The "unsharp" of the name derives from the fact that the technique uses a blurred, or "unsharp", negative image to create a mask of the original image. The unsharped mask is then combined with the positive (original) image, creating an image that is less blurry than the original. The resulting image, although clearer, may be a less accurate representation of the image's subject. It is followed by circular averaging filter to smooth the edges. Morphological operations are applied on this filtered image to detect the optic disc[7].

III. RESULTS AND DISCUSSION

The figure below shows the result output of the paper "Detection of Glaucoma using Retinal Fundus Images". It outputs the Optic disc but due to inappropriate intensity distribution in few images the disc cannot be identified easily.

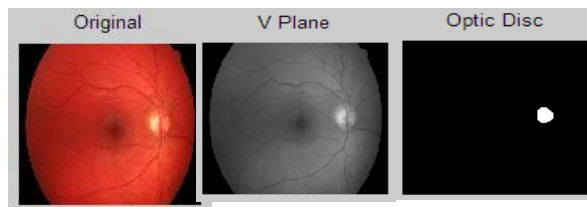


Fig. 3. Result of Paper 1

The figure below shows the output of paper titled "Automatic Detection of Optic Disc and Blood Vessels from Retinal Images Using Image Processing Techniques". Again this output gives an exact optic disc but due to improper intensity distribution, the optic disc is not detected properly.

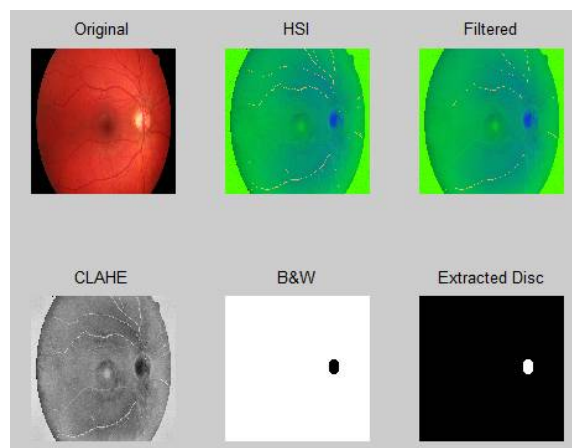


Fig. 4. Result of paper 2

The figure below shows the output of the thesis titled "Detection and Classification of Diabetic Retinopathy from Retinal Fundus Images". The optic disc is occluded by the blood vessels which makes it difficult to detect the optic disc.

International Journal of Advanced Research in Electrical, Electronics and Instrumentation Engineering

(An ISO 3297: 2007 Certified Organization)

Vol. 5, Issue 2, February 2016

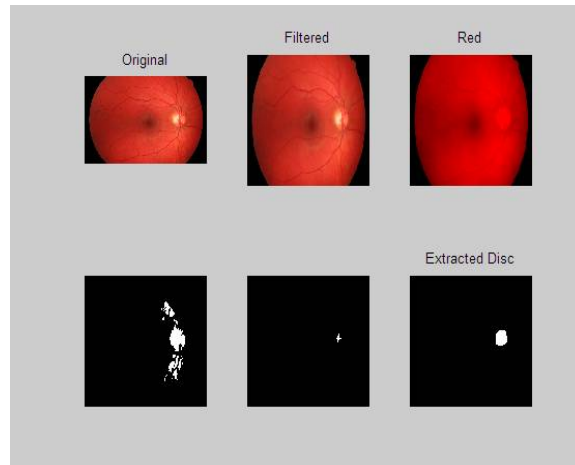


Fig. 5. Result of paper 5

The following output image is resulted by filtering the image by unsharp mask and then thresholding which blurs the image but sharpens the edges, providing a proper boundary of the optic disc.

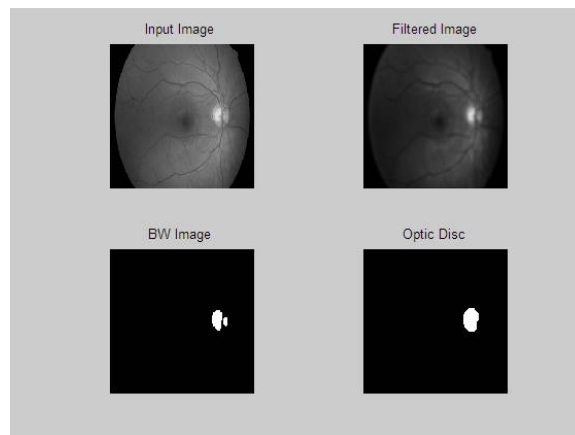


Fig. 6. Result of paper 6

IV. CONCLUSION

From this paper, we conclude that various methods are available to detect Optic disc for detection of Glaucoma, which is one of the major cause of blindness. There is a lot of ongoing research in this field. We have done some attempts to understand different techniques available till now for segmentation of optic disc, of which, morphological operations provide better and faster outputs compared to other techniques like k-means and level set segmentation.

REFERENCES

- [1] Fauzia Khan, Shoaib A. Khan, UbaidUllahYasin, IhtishamulHaq, Usman Qamar, "Detection of Glaucoma Using Retinal Fundus Images", Biomedical Engineering International Conference (BMEiCON), IEEE, 2013.
- [2] OakarPhyo, AungSoeKhaing, "Automatic Detection of Optic Disc and Blood Vessels from Retinal Images using Image Processing Techniques", IJRET, eISSN: 2319-1163 ,Volume 03 Issue 03, March 2014.
- [3] Zhuo ZHANG, BengHai LEE, Jiang LIU, Damon Wing Kee WONG, NganMeng TAN, JooHwee LIM, Fengshou YIN, Weimin HUANG, Huiqi LI, Tien Yin WONG, "Optic Disc Region of Interest Localization in Fundus Image for Glaucoma Detection in ARGALI", IEEE, 2010.
- [4] Apeksha R. Padaria and BhailalLimbasiya, "A Review Paper on Detection of Optic Disc Damage using Retinal Images", International Journal of Computer Applications (0975 – 8887), Volume 111 – No 13, February 2015.
- [5] KokelHetalNirmal, "Detection and Classification of Diabetic Retinopathy from Retinal Fundus Images", Gujarat Technological University, May 2015.
- [6] James C. Tsai, "Best of Gleams", Gleams, January 2008
- [7] Theertham, "Programmer's Corner", All About Circuits, Jun 11, 2012.